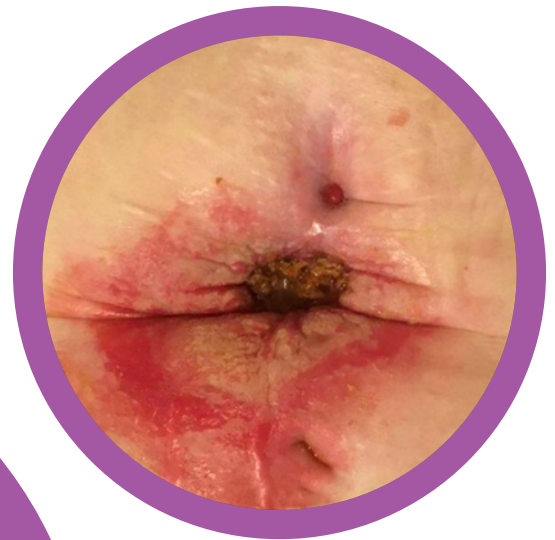
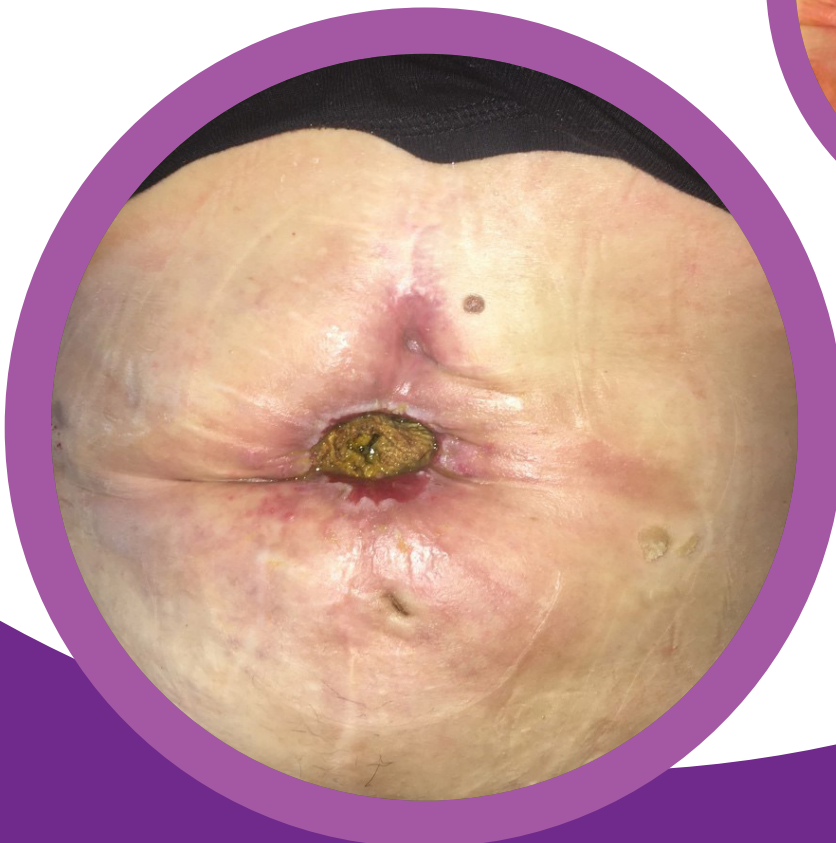
# Enterocutaneous fistula post mesh repair of incisional hernia

Case study submitted by:  
Kate Slattery, Community Stoma Nurse, Ireland

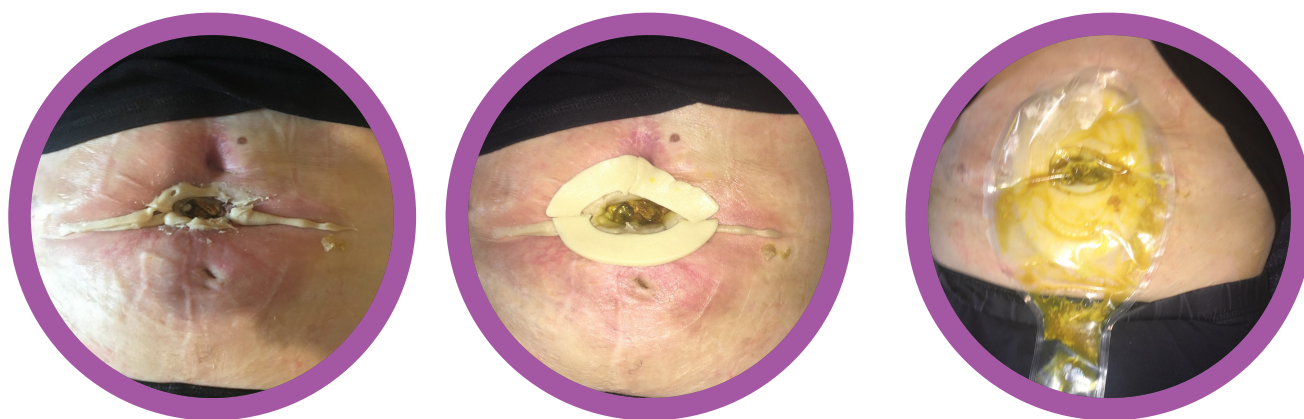
## PATIENT HISTORY

- 57 year old woman.
- Incisional hernia repair with mesh fixation.
- 2 days post op required Emergency laparotomy for bowel obstruction.
- Subsequently developed an enterocutaneous fistula.
- Several weeks in ICU / 4 months in hospital.



## CARE MANAGEMENT PLAN

- Initially managed with absorbent dressings.
- Peri-fistula skin became extremely macerated and painful.
- Various pouches with seals and paste were trialed with Coloplast ring and paste. Both flat and convex were trialed but pouch leaked within hours.
- Fistula management and peri-fistula skin management remained a difficult challenge for approximately 5 months



## SOLUTION

- Since September 2018, the lady is using the eakin **Wound Pouch™**.
- Self management of pouch changes between the patient and her family.
- Average wear time of 48 hours.
- Very occasional leakage due to changing body shape / contours.

## PRODUCT USED

Medium eakin **Wound Pouch™** 839261  
2 x eakin **Cohesive®** stomawrap 839006

