

for protecting paediatrics delicate skin and combatting peristomal skin damage

Case study submitted by Claire Murphy,
Community Stoma Care Nurse, U.K.

Background

- 2-year-old girl.
- Premature Birth 27+4 Weeks Gestation.
- Necrotising Enterocolitis – Bowel resection and subsequent Short Gut Syndrome resulting in an ileostomy formation.
- Complex medical history including liver transplant, chronic lung disease and recurrent Klebsiella Urine Infections.

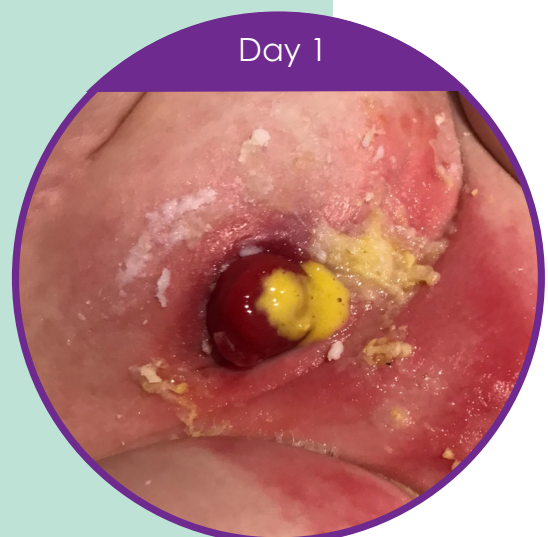Problems Experienced

- Compromised peristomal skin as a result of both leaks and skin sensitivity. As a result, causing great discomfort to the little girl and concern for her parents.
- Previous ostomy seals had caused skin irritation and were difficult to remove from the skin, causing further soreness.
- Multiple pouches trialled without success.
- Antibiotics from urine infections had weakened the immune system and contributed to episodes of sore skin.
- Daily routine of at least 6 pouch changes and when skin was too sore and wet to apply another pouch, a pad and Ilex paste were used.

Nurse Advice

Day 1: A soft convex pouch was already being used so new to the market eakin **freeseal**[®] was trialled. eakin **freeseal**[®] was chosen due to it's thinness, at just 1.8mm thin it was deemed perfect for convexity.

In addition, eakin **freeseal**[®] was chosen as it is absorbent, making it effective at stopping leaks, and protecting against skin damage. The seal is also easy to remove, and able to peel away in one piece, therefore prevents damaging skin when removing and ensures a simpler pouch change.



“ This small ring has made such a difference ”

The child's mother commented:
*“This small ring has made such a difference,
my daughter's skin is in much better condition
and the pouch now stays on for 24 hours. The
seal stays in place and Lucy is back to playing
without experiencing the leaks.”*

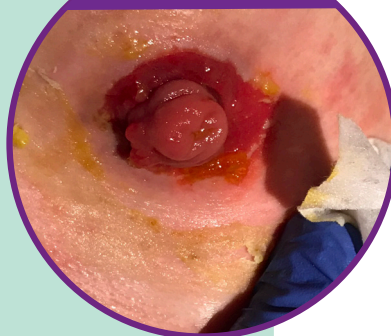
Solution with eakin freeseal[®]

Day 5: By the nurse's second visit, the little girl's skin was improving and her parents were able to achieve approximately 8 hours wear time. No further leakages were experienced.

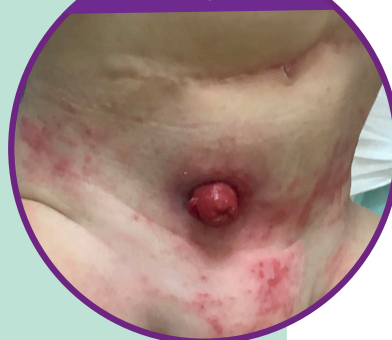Day 9: Skin had further improved with obvious change in the circumference of the stoma.

Day 12: The skin had fully healed and wear time had extended to 24 hours and still using the soft convex and eakin freeseal[®] system with no further leaks experienced.

Day 5



Day 9



Day 12

